

Anisakis simplex-induced anaphylaxis

Chisho Hoshino · Masashi Narita

Received: 25 October 2010 / Accepted: 20 December 2010 / Published online: 22 January 2011
© Japanese Society of Chemotherapy and The Japanese Association for Infectious Diseases 2011

Abstract In recent years, *Anisakis simplex* has been shown to be an important etiologic agent responsible for food allergy and for gastrointestinal anisakiasis. We report a 61-year-old woman presenting with generalized urticaria and subsequent anaphylaxis after ingestion of raw mackerel. She rapidly recovered with administration of epinephrine and endoscopic extraction of an *A. simplex* larva. Serologic testing revealed specific IgE antibody to *A. simplex* was positive whereas that to mackerel was negative. She was diagnosed as IgE-mediated hypersensitivity to *A. simplex*. Patients diagnosed as fish-related or idiopathic allergy should be examined for evidence of *Anisakis*-induced allergy.

Keywords *Anisakis simplex* · Urticaria · Anaphylaxis · Food allergy · IgE

Introduction

Anisakis simplex is a common nematode that parasitizes marine fish and mammals. Humans can be accidental hosts through ingestion of parasitized fish. *Anisakis* infestation of the human digestive tract is known to cause “gastrointestinal anisakiasis”, which manifests as acute epigastric pain mimicking the clinical features of gastric peptic ulcer or other inflammatory abdominal disorders. Recently, it has been confirmed that *A. simplex* is also responsible for acute allergic disorders after ingestion of parasitized fish. Here, we report a case presenting with *Anisakis*-induced anaphylaxis

after ingestion of raw mackerel. The responsibility of *Anisakis* allergen for food allergy, diagnosis, and prevention of *Anisakis*-induced hypersensitivity is discussed.

Case report

A 61-year-old woman presented to the emergency department of our hospital with generalized itchy, erythematous hives 2 h after ingestion of raw mackerel (Japanese *sashimi*). During the physical examination, she abruptly complained of dyspnea and chest tightening. The blood pressure was 56/30 mmHg. She immediately received intramuscular epinephrine 0.6 mg and intravenous hydrocortisone 100 mg with good response. The next day, she was admitted to our hospital because she exhibited persistent skin manifestation and developed fever and vague abdominal discomfort 8 h after the onset. She had no personal and family history of allergic disorders. On admission, her temperature was 38.2°C, the blood pressure was 140/60 mmHg and the pulse was 90 beats per minute. There were generalized erythematous hives, mainly on the trunk and extremities, whereas the conjunctiva and oral mucosa showed no signs of allergy. Auscultation of the chest revealed no wheezes or crackles. On abdominal findings, mild tenderness was noted in the epigastrium with normal bowel sounds. Blood study on the next day of glucocorticoid administration showed the white-cell count was 11,800/ μ L with 85% neutrophils, 10.4% lymphocytes, and 0.6% eosinophils. Serum chemistry revealed normal levels of serum transaminases, creatinine, and electrolyte. On upper endoscopy on the second hospital day, the presence of an *A. simplex* larva in the anterior wall of the gastric corpus was noted (Fig. 1). In addition, diffuse gastric erosion was noted predominantly in the corpus of

C. Hoshino (✉) · M. Narita
Ohta-Nishinouchi Hospital General Internal Medicine,
1-5-20 Nishinouchi, Koriyama, Fukushima 963-8025, Japan
e-mail: gim-hoshino@ohta-hp.or.jp

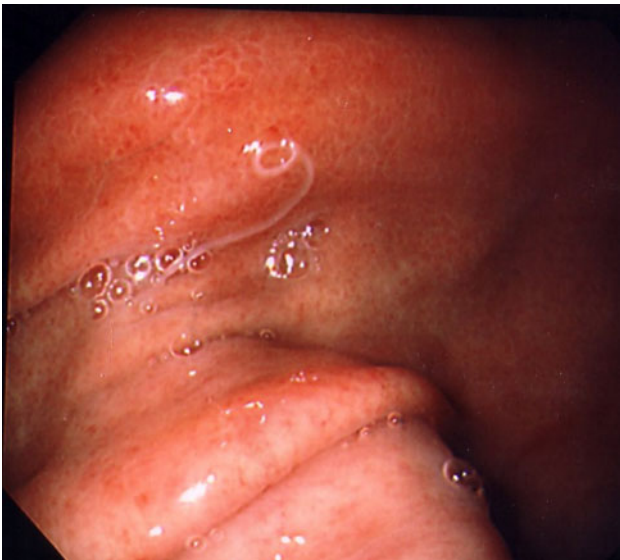

Fig. 1 Upper endoscopy showed the presence of an *A. simplex* larva in the anterior wall of the gastric body

the stomach (Fig. 2a, b). Histopathologic examination was not performed. The abdominal discomfort subsided within several hours and skin manifestation disappeared within 4 days after endoscopic removal of the worm. The results of allergy evaluation were as follows: total serum IgE was elevated (670 IU/mL) and specific IgE antibody to *A. simplex* was positive (26.2 IU/mL) by fluoroenzyme immunoassay (Pharmacia, Uppsala, Sweden), while specific IgE to mackerel was negative (<0.35 IU/mL). Given the clinical and laboratory findings, the patient was diagnosed as *Anisakis*-induced hypersensitivity and not mackerel-induced hypersensitivity. She has had no further acute allergic symptoms since she began to avoid raw seafood.

Discussion

A. simplex is a nematode that parasitizes sea mammals. Common intermediate hosts include the codfish, hake, sardine, anchovy, salmon, tuna, mackerel, and squid. Humans can be accidental hosts who acquire the third-stage larvae of *A. simplex* by ingestion of contaminated fish.

In Japan, it has been known for a long time that ingestion of raw fish can cause urticaria, and some sort of protein in the fish meat was thought to be the principal antigen. However, Kasuya et al. reported that all of 11 patients with mackerel-related urticaria had a positive reaction to *A. simplex* larval antigen on scratch test, whereas none reacted to mackerel antigen [1]. Since then, numerous cases with *Anisakis*-induced allergy ranging from isolated urticaria to life-threatening anaphylactic shock have been

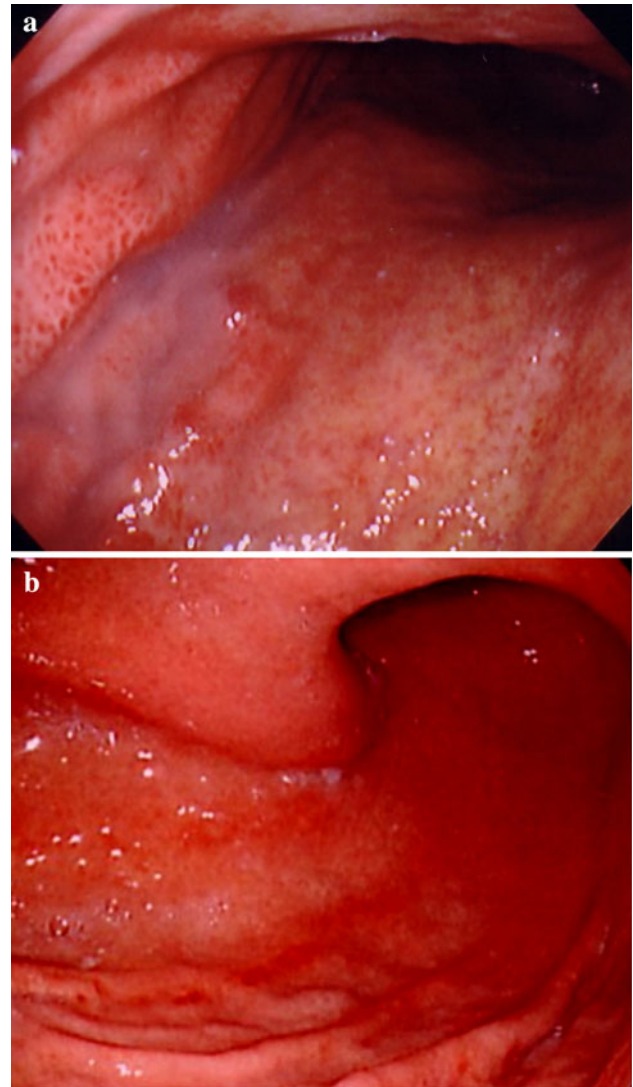


Fig. 2 On upper endoscopy, diffuse gastric erosion was noted predominantly in the corpus of the stomach (a upper corpus of the stomach, b lower corpus of the stomach)

reported in humans [2–4]. In addition, gastrointestinal anisakiasis may also be because of allergic reaction of the gastrointestinal tract against *A. simplex* given the evidence that patients with gastrointestinal anisakiasis histopathologically had the presence of infiltration of eosinophils in the gastrointestinal wall [5] and were invariably positive on skin prick tests against *A. simplex* [6]. In our case, the epigastric discomfort probably occurred as an allergic reaction to *A. simplex* because gastric erosion involved the entire stomach, and was not localized to the site of the *Anisakis* infestation.

Sensitization to *A. simplex* is more prevalent than expected and contributes a great deal to food allergy. According to recent studies, *A. simplex* was the most important hidden food allergen in the adult population

presenting with acute or chronic urticaria [2, 7] and was responsible for as much as 10% of the anaphylaxis previously diagnosed as idiopathic [8]. Thus, patients previously diagnosed as fish-related or idiopathic allergy should be examined for evidence of *Anisakis*-induced allergy.

Diagnosis of *Anisakis*-induced allergy is now based on skin prick test or measurement of serum specific IgE using crude parasite antigens. To date, more purified allergens have been identified with very variable molecular weights [4]. Crossed radioimmuno-electrophoresis (CRIE) showed that sensitized patients had serum IgE to several different allergens in a crude extract of *A. simplex* and there was a wide range of individual variability in their reactivity to each allergen [9], which could explain the diverse clinical manifestations of *Anisakis*-induced allergy. However, it still remains unknown whether an allergen involved in the anaphylaxis is identical with that in other allergic manifestations because serologic tests for these purified antigens are not yet commercially available.

There is no consensus concerning dietary restrictions for patients with *Anisakis*-induced allergy. Some authors have claimed that *A. simplex* sensitized patients tolerate ingestion of dead larvae [10]. In contrast, others claimed that cooking might not diminish the potency of their allergens [11] and recommended a strict diet with complete avoidance of fish [12]. Trujillo et al. [13] reported that raw fish-free diets could prevent new anaphylactic episodes in patients who previously had *Anisakis*-induced acute urticaria or anaphylaxis. Thus, avoidance of raw fish, at least, is essential to prevent further critical allergic reaction to *A. simplex*. In our case, no strict dietary restriction with complete avoidance of seafish has been required because no further allergic reaction has been induced by thorough cooking of seafish.

In conclusion, endoscopic examination should be considered in patients with allergic symptoms after ingestion of raw fish, and patients previously diagnosed as fish-related or idiopathic allergy should be examined for evidence of *Anisakis*-induced allergy.

References

1. Kasuya S, Hamano H, Izumi S. Mackerel-induced urticaria and *Anisakis*. *Lancet*. 1990;335:665.
2. Del Pozo MD, Audicana M, Diez JM, Munoz D, Ansotegui JJ, Fernandez E, et al. *Anisakis simplex*, a relevant etiologic factor in acute urticaria. *Allergy*. 1997;52:576–9.
3. Moreno-Ancillo A, Caballero MT, Cabañas R, Contreras J, Martín-Barroso JA, Barranco P, et al. Allergic reactions to *Anisakis simplex* parasitizing seafood. *Ann Allergy Asthma Immunol*. 1997;79:246–50.
4. Antón J, Escudero R, Fernández-Benítez M. Anaphylaxis induced by *Anisakis*. *Allergol Immunopathol (Madr)*. 2008;36:53–5.
5. Del Pozo V, Arrieta I, Tuñón T, Cortegno I, Gomez B, Cárdena B, et al. Immunopathogenesis of human gastrointestinal infection by *Anisakis simplex*. *J Allergy Clin Immunol*. 1999;104:637–43.
6. Domínguez-Ortega J, Martínez-Alonso JC, Alonso-Llamazares A, Arguelles-Grande C, Chamorro M, Robledo T, et al. Measurement of serum levels of eosinophil cationic protein in the diagnosis of acute gastrointestinal anisakiasis. *Clin Microbiol Infect*. 2003;9:453–7.
7. Daschner A, Vega de la Osada F, Pascual CY. Allergy and parasites reevaluated: wide-scale induction of chronic urticaria by the ubiquitous fish-nematode *Anisakis simplex* in an endemic region. *Allergol Immunopathol (Madr)*. 2005;33:31–7.
8. Audicana MT, Kennedy MW. *Anisakis simplex*: from obscure infectious worm to inducer of immune hypersensitivity. *Clin Microbiol Rev*. 2008;21:360–79.
9. Arlian LG, Morgan MS, Quirce S, Marañón F, Fernández-Caldas E. Characterization of allergens of *Anisakis simplex*. *Allergy*. 2003;58:1299–303.
10. Sastre J, Lluch-Bernal M, Quirce S, Arrieta I, Lahoz C, Del Amo A, et al. A double-blind, placebo-controlled oral challenge study with lyophilized larvae and antigen of the fish parasite, *Anisakis simplex*. *Allergy*. 2000;55:560–4.
11. Audicana L, Audicana MT, Fernández de Corres L, Kennedy MW. Cooking and freezing may not protect against allergenic reactions to ingested *Anisakis simplex* antigens in humans. *Vet Rec*. 1997;140:235.
12. Gracia-Bara MT, Matheu V, Zubeldia JM, Rubio M, Ordoqui E, López-Sáez MP, et al. *Anisakis simplex*-sensitized patients: should fish be excluded from their diet? *Ann Allergy Asthma Immunol*. 2001;86:679–85.
13. Trujillo MJ, Rodríguez A, Gracia Bara MT, Matheu V, Herrero T, Rubio M, et al. Dietary recommendations for patients allergic to *Anisakis simplex*. *Allergol Immunopathol (Madr)*. 2002;30:311–4.